

Stethoscopy for Dummies

An interactive and informative session designed to enhance your knowledge and understanding of the use of your stethoscope, while identifying common and critical lung, heart, and voice sounds in the emergency setting.

1997, 1999, 2003, 2010, 2016 by Bob Page, M.Ed, NRP, CCP

Objectives

By the end of this session, participants will be able to:

- ❑ Identify the parts of a stethoscope including the tubing, earpiece, and chestpiece.
- ❑ Describe the various types of stethoscopes and the advantages and disadvantages of each type.
- ❑ Describe how to properly wear a stethoscope for optimal output.
- ❑ Describe the 6 basic sites for chest auscultation of lung sounds.
- ❑ Given various lung sound recordings, identify normal bronchovesicular sounds, wheezing, rhonchi, stridor, crackles, grunting and friction rubs.
- ❑ Describe the purpose and use of voice sounds such as bronchophony, egophony and whispered pectoriloquy.
- ❑ Discuss various ways to improve your abilities to perform and improve auscultation techniques.

Outline and Plan of Action

Stethoscopy for Dummies



I. Introduction to the Stethoscope

A. Why use a stethoscope? Human hearing is optimized at 1000hz, most sounds from the chest are heard between 20-600hz.

Stethoscopes will pick up lower frequency sounds, increase them to a frequency easily heard, and amplify the sound. In order to hear certain sounds, your scope has to of sufficient quality to "pick up all frequencies" so you can hear them clearly.

B. Earpiece

- 1. Soft and supple**
- 2. Should seal completely**
- 3. Made of different material**
- 4. Choose what is comfortable to you**
- 5. Clean frequently with alcohol**

C. Tubing

- 1. Plastic or rubber, or composite**
- 2. 10-15" long**
- 3. Twin tube or mono**
- 4. Size does not matter acoustically**

D. Chestpiece

- 1. Diaphragm - High Frequency**
- 2. Bell - Low Frequency**
- 3. Dual headed**
- 4. Enhanced**
- 5. Amplified**
- 6. Recording**

II. Types of Stethoscopes

A. El-Cheap-o

1. Single headed (diaphragm only)
2. Disposable (should be anyway)
3. Not the best sound quality
4. Some are actually dual headed!

B. Sprague Rappaport. (Cheap knockoff of German original)

1. Starter stethoscope (one frequency 200hz)
2. Twin tubes
3. Dual headed (5 in one!)
4. Less than \$20.00


C. Professional Quality

1. Littmann

- a) Classic II (entry level)
- b) Master Classic (entry level)
- c) Cardiology III (cardiology rated)
- d) Master Cardiology (cardiology rated)

2. Tunable Diaphragm (Littmann Patent)

- a) High frequency - Diaphragm Press down just hard enough to leave a ring on their skin
- b) Low Frequency sounds-light touch that does leave a ring



3. Electronic scopes

- a) Littmann 3200
- b) Think labs

D. Other Specialty Scopes

- 1. Cardioscope (headphones)
- 2. Doppler
- 3. Aided sound

III. Use of the Stethoscope

A. How to wear it


- 1. ear canals angle forward
- 2. so should stethoscope

B. Using it on someone

- 1. direct skin contact
- 2. warm up the scope
- 3. optimize the environment
- 4. concentrate!

C. Diaphragm vs. Bell

- 1. Diaphragm is used for high pitched sounds
 - a) Lung sounds
 - b) Voice sounds
 - c) Murmurs
 - d) Rubs



e) Press down firmly so that when lifted, a ring appears on the patient's skin

2. Bell is used for low pitched sounds

a) Blood pressure (Korotkoff sounds)

b) Heart sounds, s3, s4, gallops

c) Lightly lay the bell on the skin for contact but do not push down.

d) Carotid Bruits

D. How/Where to Listen

1. Anterior chest: mid clavicular, 1" below collarbone

a) Have the patient breath normally through their MOUTH

b) Listen to both sides and compare

c) Rhonchi, stridor best heard here

2. Laterally: 5th intercostal space, mid clavicular

a) Wheezes heard and differentiated

3. Posterior bases: back below shoulder blades

a) Best place to hear crackles

E. Infants/small children

1. Smaller surface area means it is easy to transfer sounds across midline especially with an adult sized scope

2. Listen mid clavicular line just under arm pits

IV. Normal Lung Sounds

A. Tracheal Sounds: High pitched tubular sounds heard on inhalation and exhalation with equal intensity and duration. Heard

over the trachea with the diaphragm. Have the patient breathe normally. Assess tracheal sounds when suspect inhalation injury or possibly inflammatory process. Can also be used to hear air going around ET Tube cuff. Stridor is the abnormal sound heard here.

B. Bronchial Sounds: High Pitched sounds heard over the manubrium equally on inhalation and exhalation. Heart sounds can frequently be heard easily as you are listening over a bone on top of the heart. This is also the approximate location of the carina. Not a routine assessment but can be used whenever upper airway obstructions are possible. Stridor is the abnormal sound heard here.

C. Normal Bronchovesicular sounds: Sounds normally heard as air goes through large and smaller airways. Sounds are typically a little louder on inhalation, but taper off in pitch during exhalation. This area is the 2nd IC space mid clavicular. This is over each individual bronchial area and does include some vesicular tissue. Common sounds heard here are rhonchi (which is really a course crackle) meaning thick mucous in the bronchial tubes suggesting bronchitis, or sometimes pneumonia. Listen to both sides in similar fashion. Have the patient breathe normally. This is a routine assessment that will be done on every patient contact.

D. Normal Vesicular Sounds: Heard in the 5th intercostal space mid-axillary line or the posterior bases. Normal for this area would be obviously louder inspiration, followed by a brief expiratory sounds that rapidly tapers off. The sounds will be filtered, not tubular. The expiratory sounds are absorbed by the lung tissue. For this reason, many clinicians erroneously report these as "diminished lung sounds" in the bases. Compared to bronchovesicular or tracheal, they are. But they are a normal finding for this area. Loud sounds heard on expiration in the vesicular fields almost always indicated some kind of obstruction.

E. Stridor

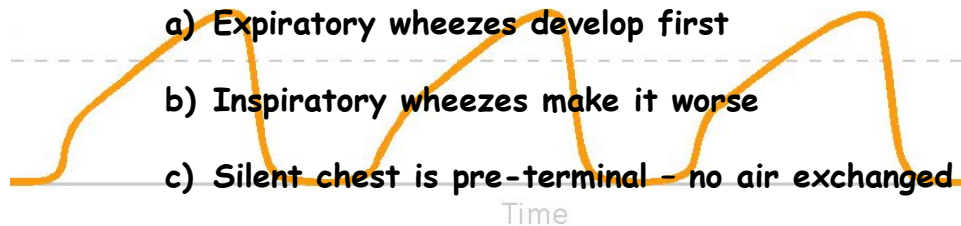
1. High pitched musical sound heard over the tracheal or bronchial area on inhalation and sometimes exhalation
2. Suggestive of upper airway obstruction

F. Rhonchi (also known as coarse crackles)

1. Coarse rattling sound heard early on exhalation or inhalation in the bronchovesicular area.
2. Caused as air passes through mucous
3. "Congestion" sounds heard in bronchitis and pneumonia

G. Wheezes

1. Musical sound heard as air passes through narrowed airway. Can be monophonic or polyphonic
2. Polyphonic wheezes commonly associated with bronchospastic diseases such as asthma, COPD, and anaphylaxis.



3. Polyphonic wheezes have multiple tones secondary to various levels of bronchospasms.
4. Monophonic Wheezes have single tone secondary to an inflammatory process.

H. Crackles (Location, Location, Location)

1. Fine or medium bubbling or “crackling” sound heard first and best in the posterior bases.
2. Course crackles heard as a result of air passing through liquid in alveoli i.e. pulmonary edema, or exudates in Pneumonia, or in ARDS.
3. Fine crackles in fibrosis and effusion sound like hair rubbing between your fingers.
4. Usually heard at the peak of inhalation, just before exhalation begins.

I. Pleural Friction Rub

1. Sounds painful, is painful, as in Pleurisy. Occurs frequently with pneumonia.
2. Sounds like pieces of wet leather rubbing together
3. Heard best where the patient points out his/her pain.

V Heart Sounds (basic) BONUS!!

A. Where to Listen: (see diagram page 13)

1. Normal S1 and S2

a) lub dub, lub-dub

b) S1 made as AV valves close

(1) Heard over 5th I/C space left sternal border
an 5th IC space mid clavicular

c) S2 heard as aortic/pulmonic valves close

(1) Heard over the 2nd I/C space right and left
sternal border

2. S3: third heart sound

(1) Heard with the BELL only over left sternal border

(2) Sound caused by abrupt deceleration of blood in a failing heart (Ejection fraction < 30%), (vibrations)

(3) Occurs after S1-S2 (Lub-dub-dee, TENN-a-see, S3)

3. S4: The fourth heart sound

a) Heard with the BELL only

b) Sound caused by forceful contraction of the atria against high pressure and non-compliance of the left ventricle wall

c) Occurs BEFORE S1 (Dee Lub-dub "Ken-TUCK- Ey", S4)

d) Suggests heart failure and/or hypertrophy

4. Summation Gallup

- a) Heard with the BELL and is a combination of S3 and S4**
- b) Suggest acute heart failure**

5. Murmur

- a) Heard with diaphragm over 5th I/C space mid clavicular, "graded" based on intensity of the sound heard.**
- b) Murmurs are "whooshing" sound heard in conjunction with S2 or S1**
- c) Can indicate valve problems, need further tests, can also be innocent.**

6. Pericardial Friction Rub

- a) Heard with the diaphragm over ERB's point or the left lower sternal border**
- b) Characteristic rubbing sound with crescendo heard constantly**
- c) Indicates pericarditis or other inflammatory process**

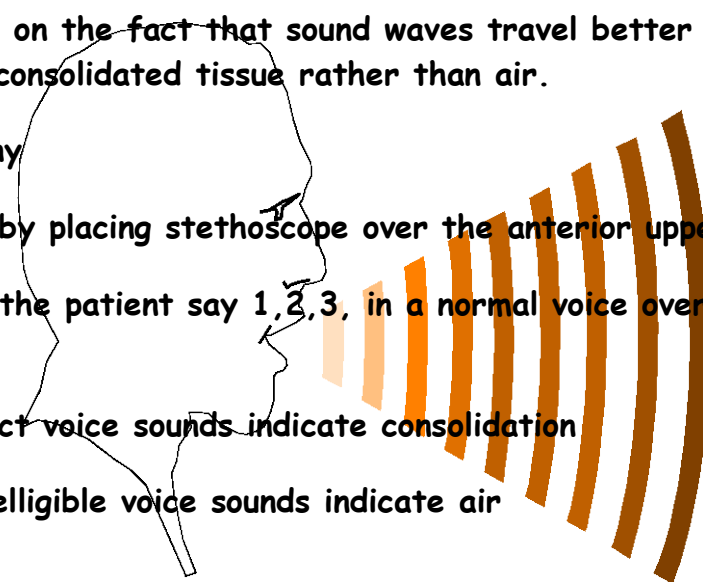
VI. Voice Sounds

A. Purpose

1. In patients with diminished breath sounds, voice sounds can aid in determining consolidation (pus or liquid filled) versus air filled areas
2. Based on the fact that sound waves travel better through consolidated tissue rather than air.

B. Bronchophony

1. Done by placing stethoscope over the anterior upper lobes
2. Have the patient say 1, 2, 3, in a normal voice over and over
3. Distinct voice sounds indicate consolidation
4. Unintelligible voice sounds indicate air

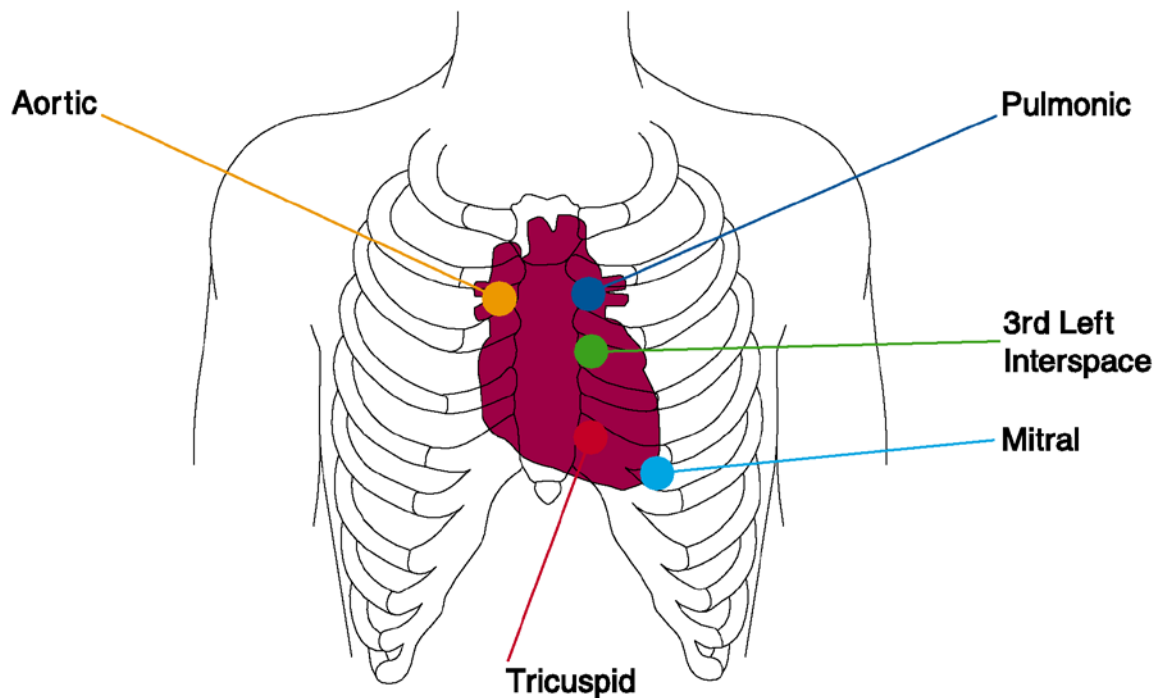


C. Egophony

1. Place stethoscope over area of diminished breath sounds
2. Have the patient say "eeeeeeeeeeee"
3. "e" will sound like "a" in an area of consolidation

D. Whispered Pectoriloquy

1. Place stethoscope over area of diminished breath sounds
2. Have the patient "whisper" 1, 2, 3 over and over
3. Sounds are distinct with consolidation



Heart Sound Auscultation Sites

Resources (for those who want to learn more)

Audio + Books:

Heart Sounds and Murmurs Barbara Erickson, Mosby Publishing

Lung Sounds: A Practical Guide: Wilkins, Hodgkins, Lopez: Mosby Publishing

Auscultation Skills: Breath and Heart Sounds: Springhouse Publishing

Delmar's Heart and Lung Sounds CD for the EMS Provider:

Delmar/Thompson Learning

Owners Manuals: Littman 3M, DRG Stethoscopes

Equipment/Sounders: <http://www.pinnacletec.com/product/breath-sounds-tutorial/> hope@pinnacletec.com

Web sites to download sounds and practice

<http://www.rale.ca/Recordings.htm> "The Rale Repository"

<http://www.wilkes.med.ucla.edu/inex.htm> "The Auscultation Assistant"